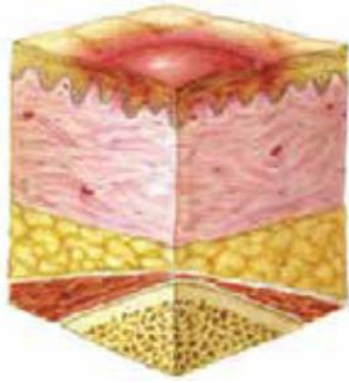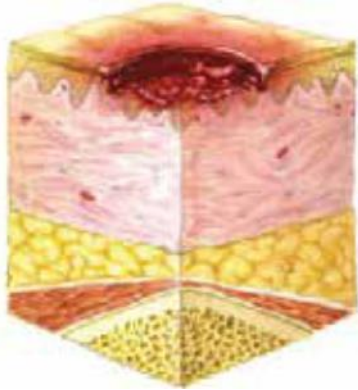


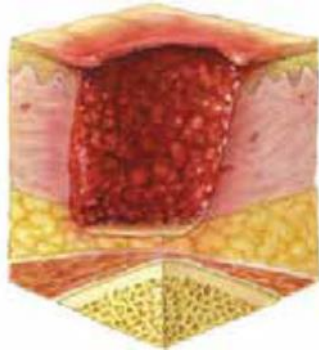
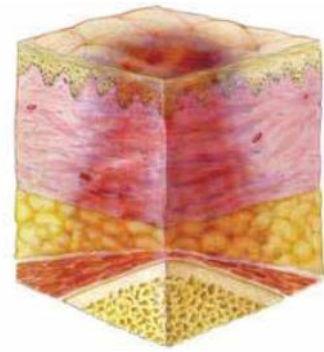


Cat 1

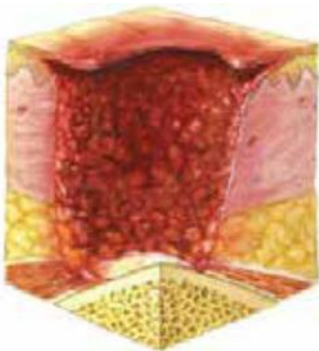
deep tissue injury



Cat 2



Cat 3



4



unstageable

	Likely Pressure Ulcer	Likely Moisture Lesion
<b>Causes</b>	Pressure and/or shear present.	Moisture present: urine, faeces, sweat and/or exudate.
<b>Location</b>	Tends to be over a bony prominence.	Lesion limited to natal cleft. Wound not over bony prominence. Peri-anal erythema and skin irritation.
<b>Shape</b>	Limited to one spot. Circular or regular shape, with exception of friction damage caused by dragging.	Diffuse—different superficial spots. In a “kissing” shape, at least one wound caused by moisture.
<b>Depth</b>	Partial thickness skin loss—top layer of skin damaged. Full thickness skin loss.	Superficial, partial thickness skin loss.
<b>Necrosis</b>	Necrosis	No necrosis
<b>Edges</b>	Distinct	Irregular
<b>Colour</b>	Red skin; non-blanching	Erythema